

# Mycobacteriosis of Fish

## I. Causative Agent and Disease

Mycobacteriosis is caused by a pleomorphic, Gram-variable, acid-fast, aerobic, non-motile group of bacteria in the family Mycobacteriaceae, genus *Mycobacterium*, that includes the human pathogen *M. tuberculosis*. There are over 190 species and 11 subspecies that are rods 0.2–0.6  $\mu\text{m}$  in diameter and 1–10  $\mu\text{m}$  long. The most common species in fish are *M. marinum*, *fortuitum*, *chelonae* and *shottsii* that cause a chronic systemic granulomatous disease affecting any or all tissues and organs. Most mycobacteria can survive within host macrophages.

## II. Host Species

Distribution is worldwide in amphibians, reptiles and 151 species of wild and cultured fish representing 40 families including many freshwater aquarium species, salmonids and marine fishes. The disease causes serious problems in cultured species, especially aquarium fish. In Alaska, the disease has occurred in sablefish, pollock and saffron cod and is likely more widespread in other fish species.

## III. Clinical Signs

Gross clinical signs of mycobacteriosis may be non-specific scale loss, dermal ulceration, emaciation, spinal defects and ascites. Internal signs include enlarged spleen, kidney and/or liver and characteristic gray or white nodules in internal organs.

## IV. Transmission

The epizootiology in fish includes horizontal transmission by contact and ingestion as established experimentally in zebrafish and early salmonid culture when raw fish were used as feed. Verti-

cal (transovarian) transmission in live bearing fishes has also been reported. Other aquatic organisms can be infected and act as vectors.

## V. Diagnosis

Presumptive diagnosis is made by histologic examination of tissues showing typical inflammatory granulomas with concentric layers of noncompressed and compressed (spindle cell layer) epithelioid cells forming discrete spherical lesions. The centers are necrotic, often containing mycobacteria visible by acid-fast stains. Fast and slow growing mycobacteria can be cultured on selective liquid and agar media providing phenotypic characteristics with definitive identification by PCR.

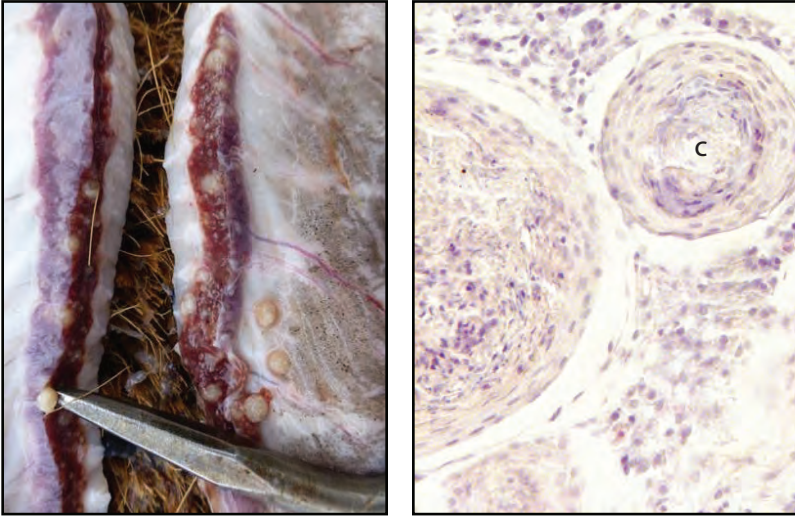
## VI. Prognosis for Host

Mycobacteriosis in fish is a chronic disease often precipitated by stress. Acute mortality in wild fish is uncommon. Long-term population declines attributed to mycobacteria are possible as suspected for Chesapeake Bay striped bass, likely exacerbated by environmental decline. There is no effective treatment for infected fish which should be culled if in a culture environment.

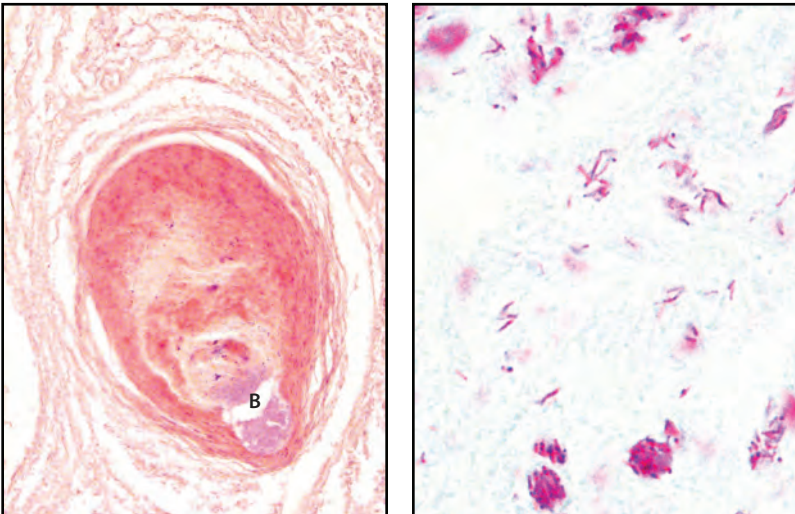
## VII. Human Health Significance

Aquatic mycobacteria pose significant zoonotic concerns, especially in immunocompromised people. *M. marinum*, *fortuitum* and *chelonae* are known human pathogens producing granulomatous skin lesions and sometimes deeper infections of peripheral tissues (with *marinum*). Infections are treatable by antibiotic therapy.

## BACTERIA



**Left:** Large round white granulomas (pointer) in the kidney and peritoneum of a sablefish (photo: Eric Forrer) caused by *Mycobacterium* sp.; **Right:** Histology of mycobacteria nodules in a Siamese fighting fish showing concentric layers of epithelioid cells with necrotic centers (C), X 400.



**Left:** Histology of sablefish granuloma in post-mortem kidney with mycobacterial colony (B) in necrotic center, X 200; **Right:** Histological acid-fast stain of mycobacteria (red) in sablefish granuloma, X 1000.